

Histologic analysis of endometriomas: what the surgeon needs to know

Ludovico Muzii, M.D.,^a Antonella Bianchi, M.D.,^b Filippo Bellati, M.D.,^c
Emanuela Cristi, M.D.,^b Milena Pernice, M.D.,^c Marzio A. Zullo, M.D.,^a
Roberto Angioli, M.D.,^a and Pierluigi Benedetti Panici, M.D.^c

^aDepartment of Obstetrics and Gynecology, and ^bDepartment of Pathology, University Campus Bio-Medico of Rome; and ^cDepartment of Obstetrics and Gynecology, University of Rome "La Sapienza," Rome, Italy

Objective: To evaluate by thorough pathologic analysis the histologic features of the endometrioma wall excised at laparoscopy.

Design: Prospective series of consecutive patients.

Setting: Tertiary care, university hospital.

Patient(s): Fifty-nine patients with ovarian endometriomas. A total of 70 cysts were examined.

Intervention(s): Patients underwent operative laparoscopy with the stripping technique for excision of the ovarian endometrioma.

Main Outcome Measure(s): A thorough histologic examination was performed on the entire cyst wall specimen.

Result(s): Histologic examination confirmed the endometriotic nature of the cyst in 100% of the cases. The inner wall of the endometrioma was covered by endometriotic tissue on 60% of the surface. The mean cyst wall thickness was 1.4 mm. The mean value of maximal depth of endometriosis penetration in the endometrioma wall was 0.6 mm. In 99% of the cases the maximal penetration of the endometriotic tissue was <1.5 mm.

Conclusion(s): In the present study, we demonstrate that the endometrioma wall contains endometriotic tissue in 100% of the cases. However, the endometriotic tissue may cover the inner cyst wall for a surface that varies between 10% and 98% of the entire wall (median value 60%). This tissue may reach a depth of 2 mm, but for most of the surface it does not penetrate >1.5 mm. These histologic data may help the gynecologic laparoscopist select the surgical approach that maximally preserves healthy ovarian tissue. (*Fertil Steril*® 2007;87:362–6. ©2007 by American Society for Reproductive Medicine.)

Key Words: Endometrioma, endometriosis, laparoscopy, stripping technique

Today, ovarian cyst excision is one of the main indications for operative laparoscopy (1). Endometriomas represent the most frequent histotype reported in operative laparoscopy series for ovarian cyst excision (2–5).

In the literature, however, histologic confirmation of the endometriotic nature of the cyst has been reported in between 0 (6) and 100% (2, 7, 8) of the excised endometriomas. This wide variability in the confirmation of the endometriotic nature of the endometrioma in the different series is particularly disturbing, because low rates of histologic confirmation may correspond to high rates of functional cysts being excised, which in turn, correspond to wrong indications to operative laparoscopy and inappropriate treatment of the functional ovarian cyst (8). On the other hand, low rates of histologic confirmation may instead be because of inadequate sampling by the pathologist, who may miss a few isolated areas of endometriosis lining an otherwise fibrotic capsule, with possible medicolegal implications for the surgeon who is treating endometriosis and finds

instead the diagnosis of a functional cyst in the pathology report.

The histologic nature of the endometrioma wall should also be thoroughly evaluated to contribute to the debate on pathogenesis of the endometrioma and to select the proper treatment accordingly. According to Brosens et al. (9), the endometrioma represents an invagination of the ovarian cortex at the site of original adhesion of the ovary to the peritoneum. Therefore, only a few spots of the internal lining are constituted by superficial endometriosis implants, whereas most part of the lining is normal ovarian cortex. Consequent to this theory comes the treatment of the ovarian endometrioma performed by Brosens et al. (9), which consists in opening of the cyst and bipolar coagulation only of superficial neovascularization areas and of the few spots visually suspect for endometriosis. If, on the other hand, Brosens' theory proves incorrect and the endometrioma is completely lined with endometriosis tissue, then the whole inner cyst surface should be treated.

Both the techniques of cyst excision and of ablation and coagulation of the cyst lining can be performed to treat the entire cyst wall. With the latter technique, however, the surgeon should be aware of the depth of penetration of the endometriosis tissue in the cyst capsule, so as to select the settings of the laser

Received January 19, 2006; revised and accepted June 30, 2006.

Reprint requests: Ludovico Muzii, M.D., Department of Obstetrics and Gynecology, University Campus Bio-Medico of Rome, Via Longoni, 83-00155 Rome, Italy (FAX: +39-06-22541456; E-mail: l.muzii@unicampus.it).

or of the electrosurgical unit appropriate to completely treat the pathologic tissue.

The information on the histologic nature of the endometrioma wall and on the depth of penetration of the endometriosis tissue into the cyst capsule is scant in the literature, being confined to only a few anecdotal reports (10, 11).

The purpose of the present study was to thoroughly examine the endometrioma wall, with complete histologic examination of the excised specimen, to assess the presence, extent, and depth of penetration of endometriosis tissue in the cyst capsule.

MATERIALS AND METHODS

From January 2002 to December 2004, 59 consecutive patients with a clinical and sonographic diagnosis of ovarian endometrioma >3 cm were included in the present trial. The patients were selected for laparoscopic management at the Department of Obstetrics and Gynecology of the Campus Bio-Medico University in Rome.

The diagnosis of an adnexal mass was made at routine gynecologic examination in 6 patients, during diagnostic workup for pelvic pain in 49, and during workup for infertility in 4. In all cases a repeat transvaginal sonogram was requested in the follicular phase of the cycle 8 to 12 weeks following the first to avoid unnecessary surgery for functional ovarian cysts (8). Patients with associated nonendometriotic ovarian pathology were excluded. No patients had deeply infiltrating endometriosis in the cul-de-sac.

All patients were premenopausal. The mean age of the patients was 32.8 ± 6.2 years (mean \pm SD).

The ovarian endometrioma was monolateral in 48 cases (always >3 cm), and bilateral in 11 patients (in these patients, at least one of the two cysts was >3 cm). Associated, small (<1 cm) endometriomas were not considered in the tabulation of data. Therefore, a total of 70 cysts were excised. The mean diameter of the cysts was 5.1 ± 2.4 cm. The mean Revised American Society for Reproductive Medicine score (12) was 41.3 ± 22.5 .

All procedures were performed under general anesthesia. After establishing the pneumoperitoneum, an 11-mm trocar and then the 10-mm laparoscope were introduced through a vertical infraumbilical incision. Three 5-mm accessory trocars were then introduced suprapubically. An assessment of the pelvis, abdomen, and external surface of the cyst was then performed for possible evidence of malignancy. Peritoneal fluid or washing was then collected for cytologic examination.

After mobilization of the ovary, with cyst rupture always occurring, accurate rinsing of the chocolate fluid content was performed. The cyst capsule was then separated from the ovarian tissue with the stripping technique by means of repeated diverging tractions applied using two atraumatic

grasping forceps. Hemostasis was achieved with bipolar coagulation. The ovarian cortex was left open without suturing. The cyst wall was removed from the abdomen by means of an endobag. Copious amounts of lactated Ringer's solution were used to irrigate the pelvic cavity throughout the procedure.

No intraoperative complications occurred. All patients were discharged home within 48 hours of the surgery, without any major after operative complication.

Surgical specimens of the endometrioma cyst walls were fixed in 10% neutral-buffered formaldehyde, and tissue samples obtained at 0.5-cm intervals were embedded in paraffin. Two consecutive sections of 3 μ m thickness were cut from each paraffin-embedded block. Routine haematoxylin and eosin staining was performed on the sections for histopathologic examination.

For the diagnosis of endometriosis, the criteria of the technical bulletin on endometriosis of the American College of Obstetricians and Gynecologists were followed (13). In particular, two or more of the following features had to be present to diagnosis endometriosis: endometrial epithelium, endometrial glands, endometrial stroma, or hemosiderin-laden macrophages.

RESULTS

In all 70 cysts, the endometriotic nature of the cyst was confirmed. The mean cyst wall thickness was 1.4 ± 0.6 mm, considering all the sections performed in the 70 cyst walls. The maximal wall thickness for the 70 cysts was 1.8 ± 0.6 mm. Identifiable ovarian tissue (stroma, follicles, or both) inadvertently excised with the endometrioma was present in 57 (81%) of the 70 cyst wall specimens.

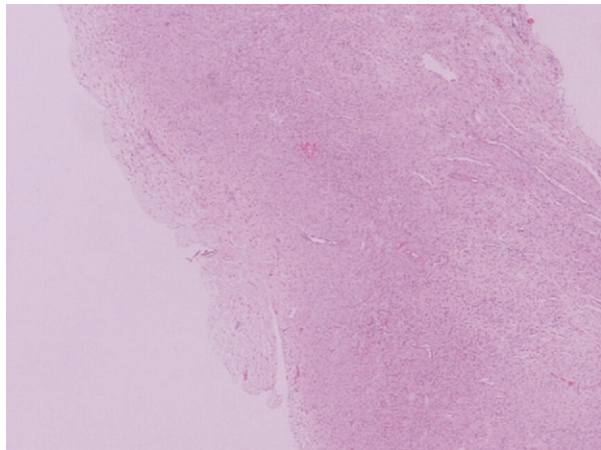
The internal surface of the cyst wall was covered by an endometrial lining in 60% of the entire area (median value), with a range of 10% to 98%. In 40% of the cyst surface (with a range of 2%–90%), no epithelium was identifiable, and the inner surface of the cyst was covered by fibrotic tissue (Fig. 1). In no case was an epithelium other than endometrial identified.

The endometriotic tissue had a mean value of maximal penetration into the cyst wall of 0.6 ± 0.4 mm, ranging from 0.1 to 2.0 mm. In all but one case (99%) the maximal endometriosis penetration was <1.5 mm, and in 61 cases (87%) the penetration was <1 mm.

In the portion of the cyst wall where the penetration of endometriosis was deeper, the total cyst wall thickness was also greater (Fig. 2). In fact, in the portion of the cyst wall where the endometriosis reached a maximal depth of penetration of >1 mm, the total cyst wall thickness (measured only at the site of maximal endometriotic penetration) was 2.4 ± 0.3 mm, versus 1.5 ± 0.6 mm for the cyst wall thickness in the specimen with ≤ 1 mm penetration ($P=.00003$).

FIGURE 1

Specimen of an endometrioma wall, with a thickness of 2.1 mm. No epithelial lining can be seen on the inner surface of the cyst wall (on the *left*). When examining the whole cyst from the same patient, only 10% of the inner surface was covered by endometriosis. Hematoxylin and eosin, original magnification 20 \times .



Muzii. Histologic analysis of endometrioma. *Fertil Steril* 2007.

DISCUSSION

Today, operative laparoscopy should be considered the “gold standard” for the approach to ovarian endometriomas. The technique to be adopted during laparoscopy to treat the endometrioma still remains a matter of debate.

The postulated pathogenesis of the endometrioma should determine the choice of appropriate treatment. Some investigators (9, 11, 14) consider the ovarian endometrioma a pseudocyst, that is, an invagination of the ovarian cortex. The accumulation of chocolate fluid inside the cyst could be because of either metaplastic transformation of the invaginated mesothelium of the ovarian cortex, which changes into mature endometrial cells (11), or production of menstrual debris from the superficial ovarian implants of endometriosis which, consequent to the invagination, lines the inside of the cyst (9).

Following the metaplasia theory, superficial vaporization of the inner wall of the endometrioma up to 0.2 mm with the KTP laser (14), or ablation with the CO₂ laser with a power setting of 40 W and continuous mode application until no pigment could be seen (11), have been indicated as the techniques of choice. Following the invagination and superficial endometriosis theory (9), fenestration of the cyst and coagulation of the few superficial implants and areas of vascularization should be regarded as the treatment of choice. If this second theory proves correct, then the histology of the cyst wall should reveal mesothelium with only a few endometriosis implants.

The same investigators (9, 11, 14) have questioned the technique of ovarian cyst stripping because it may be associated with excessive removal of ovarian tissue. As a consequence of the stripping procedure, poorer performance in IVF protocols (15) and reduced ovarian volumes (16, 17) have been reported after endometrioma excision. However, other studies report data at variance with the above-mentioned studies, both for reproductive performance in IVF protocols (18, 19) and for postoperative ovarian volumes (20).

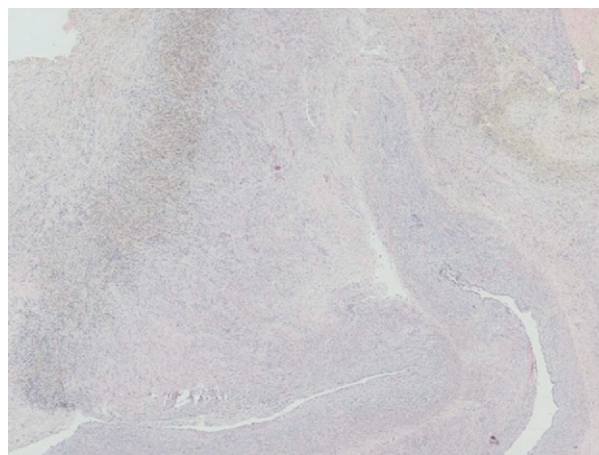
Two randomized studies (21, 22) and a systematic review (23) have been recently published, and, following these reports, cyst wall excision by the stripping technique should now be considered the treatment of choice for ovarian endometriomas. In fact, lower recurrence rates and higher pregnancy rates have been reported comparing this technique with ablation or coagulation of the endometrioma wall (21–23).

In the literature, the histologic confirmation of the endometriotic nature of the ovarian endometrioma has been reported anywhere between 0 (6) and 100% (2, 7, 8). Only a few studies report in detail the histologic nature of the endometrioma wall.

In a recent study by our group (7), all specimens taken from different parts of the endometrioma wall were con-

FIGURE 2

Specimen of an endometrioma wall, with a maximal thickness of 2.7 mm. On the inner surface of the cyst wall (*bottom right*), endometriotic tissue can be seen, which penetrates to a maximal depth of 2.0. This is the maximal depth of penetration observed in the present series. When examining the whole cyst from the same patient, 80% of the inner surface was covered by endometriosis. Hematoxylin and eosin, original magnification 20 \times .



Muzii. Histologic analysis of endometrioma. *Fertil Steril* 2007.

firmed to be endometriosis. The mean cyst wall thickness varied between 1.2 and 1.6 mm. The cyst wall was mostly covered by a thin endometrial epithelium. Most of the wall was constituted by fibrosis, whereas ovarian tissue was inadvertently excised with the endometrioma in 54% to 71% of the specimens from the different parts of the cyst. The ovarian tissue inadvertently excised with the endometrioma was present most frequently at the hilus, where it was also thicker (0.8 mm) than in the rest of the cyst wall (0.3 mm).

In a study by Martin et al. (10), 25 (61%) of 41 chocolate cysts were histologically confirmed to be endometriosis, 5 cysts (12%) were nondiagnostic, whereas 11 (27%) were corpus luteum or albicans. The histologic features of the endometriomas were endometriosis lining surrounded by fibrosis and by a rim of normal-appearing ovary. No information was provided in this report as to the thickness of the cyst wall specimen, the depth of penetration of endometriosis into the cyst capsule, or the amount and histologic features of the ovarian tissue inadvertently excised with the endometrioma wall (10). In a subsequent review, Martin (24) commented on unpublished data reporting that the depth of penetration of endometriosis into the cyst wall was always <1.5 mm.

In the present study, a complete histologic evaluation of the endometrioma wall was performed, with a thorough analysis of its inner surface and of the depth of penetration of the endometrial glands into the fibrotic capsule. We demonstrate here that the inner surface of the endometrioma is mostly constituted by endometrium, which is, however, different from the eutopic endometrium because it has a mean depth of maximal penetration of only 0.6 mm. The endometriotic tissue may cover the inner aspect of the cyst from 10% to 98% of its surface.

This data should stimulate both the clinician and the pathologist to seek a diagnosis of endometriosis with further histologic sections (which could be present only in 10% of the specimen) when the first pathologic report suggests functional or nondiagnostic features, particularly in patients with a strong clinical suspect of endometriosis, or when the ultrasonographic diagnosis of the endometrioma has been confirmed by a second sonogram performed 2 to 3 months later. In this situation, in fact, the possibility of a functional cysts is very remote (8).

In our set of data, the measurements for the depth of invasion of endometriosis into the cyst wall and the rates of endometrial epithelium covering the inner cyst surfaces were normally distributed, therefore not supporting the categorization of endometriomas in two or three different pathologic entities, as hypothesized by Nezhat et al. (25).

Given these premises, both the technique of superficial laser vaporization of the entire inner surface up to 0.2 mm (14) and the technique of "spot-by-spot" low-power bipolar coagulation of the supposed endometrial implants (9) would prove insufficient to completely treat the endometriosis

present in the cyst wall. Also, the technique of fenestration followed by complete bipolar coagulation of the cyst wall (21, 22) would determine, in most cases, the persistence of some of the endometriosis, because the tissue damage using bipolar devices may be under 0.2 mm of depth (26), which is much less than the mean depth of penetration of the endometriosis into the cyst wall.

The clinical consequence of this superficial and possibly incomplete treatment of the endometrial lining of the cyst wall could be the higher recurrence rates reported with the fenestration/ablation technique (21, 23).

The technique of cyst excision with the stripping procedure, based on the present data, undoubtedly represent a complete treatment of the endometrioma. In fact, in no case does the endometriotic tissue reach the deepest part of the specimen. Margins clear of pathology were always obtained. When the endometriosis penetrates deeper into the cyst capsule (>1 mm), the thickness of the excised cyst in that portion of the specimen is also greater (2.4 mm instead of 1.5 mm). It therefore seems that the plane of cleavage that is being developed during the stripping procedure follows the interface between the fibrotic capsule and the normal ovarian tissue, never cutting through pathologic tissue, yielding complete removal of the endometriosis.

On the other hand, the stripping procedure does not seem to represent an overtreatment, because the tissue that is being excised with the endometriosis is mostly only fibrotic. Some ovarian tissue is nevertheless present in the excised cyst wall (81% of the specimens). In the present series, with complete evaluation of the cyst wall, this obviously happens more often than previously reported (54%) with partial cyst examination (27). The ovarian tissue that is being excised, however, does not have, in most cases, the histologic (and possibly functional) features of the normal ovary (27).

A prerequisite for a complete treatment of the endometrioma respectful of the healthy ovarian tissue is a correct surgical technique, which should pay maximal attention to the development of the right plane of cleavage, and which should employ targeted bipolar hemostasis at the end of the procedure. Maximal attention should be exerted near the hilar area, where excessive traction on the endometrioma wall may cause tearing of hilar vessels, and further damage to the ovary could be determined by nontargeted coagulation (7).

In conclusion, the complete histologic evaluation of the endometrioma wall reveals that the cyst wall has some endometriosis in 100% of the cases, covering the inner aspect of the cyst for approximately 60% of its surface. The endometriotic tissue penetrates into the cyst wall for a mean depth of 0.6 mm, penetrating >1.5 mm only in rare cases.

These histologic data provide theoretic support to the stripping technique as the procedure of choice for the treatment of ovarian endometriomas.

REFERENCES

1. Chapron C, Querleu D, Bruhat MA, Madelenat P, Fernandez H, Pierre F, et al. Surgical complications of diagnostic and operative gynaecological laparoscopy: a series of 29,966 cases. *Hum Reprod* 1998;13: 867–72.
2. Marana R, Muzii L, Catalano GF, Oliva C, Marana E. Laparoscopic excision of adnexal masses. *J Am Assoc Gynecol Laparosc* 2004;11: 162–6.
3. Nezhat F, Nezhat C, Welander CE, Benigno B. Four ovarian cancers diagnosed during laparoscopic management of 1011 women with adnexal masses. *Am J Obstet Gynecol* 1992;167:790–6.
4. Canis M, Mage G, Pouly JL, Wattiez A, Manhes H, Bruhat MA. Laparoscopic diagnosis of adnexal cystic masses: a 12-year experience with long-term follow-up. *Obstet Gynecol* 1994;83:707–12.
5. Mettler L, Jacobs V, Brandenburg K, Jonat W, Semm K. Laparoscopic management of 641 adnexal tumors in Kiel, Germany. *J Am Assoc Gynecol Laparosc* 2001;8:74–82.
6. Favez J, Vogel MF. Comparison of different treatment methods of endometriomas by laparoscopy. *Obstet Gynecol* 1991;78:660–5.
7. Muzii L, Bellati F, Bianchi A, Palaia I, Mancini N, Zullo MA, et al. Laparoscopic stripping of endometriomas: a randomized trial on different surgical techniques. Part II: pathological results. *Hum Reprod* 2005;20:1987–92.
8. Muzii L, Benedetti Panici P. Surgery for functional cysts: is it unnecessary? *J Am Assoc Gynecol Laparosc* 2001;8:616–8.
9. Brosens IA, Van Ballaer P, Puttemans P, Deprest J. Reconstruction of the ovary containing large endometriomas by an extraovarian endoscopic technique. *Fertil Steril* 1996;66:517–21.
10. Martin DC, Berry JD. Histology of chocolate cysts. *J Gynecol Surg* 1990;6:43–6.
11. Donnez J, Nisolle M, Gillet N, Smets M, Bassil S, Casanas-Roux F. Large ovarian endometriomas. *Hum Reprod* 1996;11:641–6.
12. American Society for Reproductive Medicine. Revised American Society for Reproductive Medicine classification of endometriosis: 1996. *Fertil Steril* 1997;67:817–21.
13. American College of Obstetricians and Gynecologists. Medical management of endometriosis. *ACOG Practice Bulletin* no.11, 1999.
14. Jones KD, Sutton C. Endometriotic ovarian cysts: the case for ablative surgery. *Gynecol Endosc* 2001;10:281–7.
15. Garcia-Velasco JA, Mahutte NG, Corona J, Zuniga V, Giles J, Arici A, et al. Removal of endometriomas before in vitro fertilization does not improve fertility outcomes: a matched, case-control study. *Fertil Steril* 2004;81:1194–7.
16. Exacoustos C, Zupi E, Amadio A, Szabolcs B, De Vivo B, Marconi D, et al. Laparoscopic removal of endometriomas: sonographic evaluation of residual functioning ovarian tissue. *Am J Obstet Gynecol* 2004;191: 68–72.
17. Candiani M, Barbieri M, Bottani B, Bertulesi C, Vignali M, Agnoli B, et al. Ovarian recovery after laparoscopic enucleation of ovarian cysts: insights from echographic short-term postsurgical follow-up. *J Minim Invasive Gynecol* 2005;12:409–14.
18. Marconi G, Vilela M, Quintana R, Sueldo C. Laparoscopic ovarian cystectomy of endometriomas does not affect the ovarian response to gonadotropin stimulation. *Fertil Steril* 2002;78:876–8.
19. Canis M, Pouly JL, Tamburro S, Mage G, Wattiez A, Bruhat MA. Ovarian response during IVF-embryo transfer cycles after laparoscopic ovarian cystectomy for endometriotic cysts of >3 cm in diameter. *Hum Reprod* 2001;16:2583–6.
20. Muzii L, Bellati F, Plotti F, Mancini N, Palaia I, Zullo MA, et al. Ultrasonographic evaluation of postoperative ovarian cyst formation after laparoscopic excision of endometriomas. *J Am Assoc Gynecol Laparosc* 2004;11:457–61.
21. Beretta P, Franchi M, Ghezzi F, Busacca M, Zupi E, Bolis P. Randomized clinical trial of two laparoscopic treatments of endometriomas: cystectomy versus drainage and coagulation. *Fertil Steril* 1998;70: 1176–80.
22. Alborzi S, Momtahan M, Parsanezhad ME, Dehbashi S, Zolghadri J, Alborzi S. A prospective, randomized study comparing laparoscopic ovarian cystectomy versus fenestration and coagulation in patients with endometriomas. *Fertil Steril* 2004;82:1633–7.
23. Hart R, Hickey M, Maouris P, Buckett W, Garry R. Excisional surgery versus ablative surgery for ovarian endometriomata: a Cochrane Review. *Hum Reprod* 2005;20:3000–7.
24. Martin DC. Tissue effects of lasers. *Semin Reprod Endocrinol* 1991;9: 127–37.
25. Nezhat F, Nezhat C, Allan CJ, Metzger DA, Sears DL. A clinical and histological classification of endometriomas: implications for a mechanism of pathogenesis. *J Reprod Med* 1992;37:771–6.
26. Baggish MS, Tucker RD. Tissue actions of bipolar scissors compared with monopolar devices. *Fertil Steril* 1995;63:422–6.
27. Muzii L, Bianchi A, Croce C, Mancini N, Benedetti Panici P. Laparoscopic excision of ovarian cysts: is the stripping technique a tissue-sparing procedure? *Fertil Steril* 2002;77:609–14.