

# Assessment of ovarian reserve after cystectomy versus ‘one-step’ laser vaporization in the treatment of ovarian endometrioma: a small randomized clinical trial

M. Candiani<sup>1</sup>, J. Ottolina<sup>1,\*</sup>, E. Posadzka<sup>2</sup>, S. Ferrari<sup>1</sup>,  
L. M. Castellano<sup>1</sup>, I. Tandoi<sup>1</sup>, L. Pagliardini<sup>3</sup>, A. Nocuń<sup>4</sup>, and R. Jach<sup>2</sup>

<sup>1</sup>Gynaecological Surgery and Endometriosis Departmental Unit, San Raffaele Scientific Institute, Milan, Italy <sup>2</sup>Endocrinological Gynecology Department, Jagiellonian University, Collegium Medicum, Cracow, Poland <sup>3</sup>Division of Genetics and Cell Biology, IRCCS San Raffaele Scientific Institute, Milan, Italy <sup>4</sup>Centre of Ultrasound Diagnostic MWU DobreUSG, Cracow, Poland

\*Correspondence address. Gynaecological Surgery and Endometriosis Departmental Unit, San Raffaele Scientific Institute, Via Olgettina 60, 20132 Milan, Italy. Tel: +39-022-643-2653; Email: ottolina.jessica@hsr.it

Submitted on February 27, 2018; resubmitted on July 30, 2018; accepted on September 19, 2018

**STUDY QUESTION:** Does CO<sub>2</sub> laser vaporization offer better results in treating endometrioma in terms of ovarian reserve preservation compared to traditional cystectomy?

**SUMMARY ANSWER:** Assessing both antral follicle count (AFC) and serum anti-Müllerian hormone (AMH) levels as measures of ovarian reserve, the results suggest that CO<sub>2</sub> technology may be an alternative treatment for endometrioma, causing minimal damage to adjacent healthy ovarian tissue.

**WHAT IS KNOWN ALREADY:** Excisional surgery has been questioned as an ideal surgical approach for endometriomas because it is associated with potential reduction of ovarian reserve. Recently, vaporization with CO<sub>2</sub> laser in-line-of-sight, according to the ‘three-step procedure’, has been proposed as the best method to preserve ovarian function. However, no randomized controlled trials have been conducted to compare cystectomy and ‘one-step’ CO<sub>2</sub> fiber laser vaporization (without GnRH agonist therapy) with respect to the ovarian reserve.

**STUDY DESIGN, SIZE, DURATION:** A multicentre randomized clinical trial including 60 patients was performed between July 2017 and February 2018. Computerized randomization was conducted to allocate them in a proportion of 1:1 either to Group 1 (laparoscopic stripping: cystectomy) or Group 2 (CO<sub>2</sub> laser vaporization). Patients in Group 1 underwent a standardized laparoscopic stripping technique; patients in Group 2 underwent drainage of the cyst content, biopsy and vaporization of the internal wall with a CO<sub>2</sub> fiber laser. Patients underwent pelvic ultrasound examination to determine the AFC and blood sampling to determine AMH levels before surgery and at 1- and 3-month follow-up.

**PARTICIPANTS/MATERIALS, SETTING, METHODS:** Patients undergoing surgery for symptomatic endometriomas (infertility and/or pelvic pain) larger than 3 cm were randomized in two groups according to the surgical technique. Patients aged ≥40 years, or with deep infiltrating endometriosis/adenomyosis, or previously submitted to surgical procedures on the ovaries or to hysterectomy were excluded from the study. The primary endpoint was the comparison of intra-group AFC changes before and after surgery (ΔAFC) between the two groups (ΔAFC Group 1 versus ΔAFC Group 2). The secondary endpoint was the modification of serum AMH before and after surgery (ΔAMH) between the two groups (ΔAMH Group 1 versus ΔAMH Group 2).

**MAIN RESULTS AND THE ROLE OF CHANCE:** The AFC of the operated ovary was significantly increased in Group 2 (laser vaporization) compared with Group 1 (cystectomy) after surgery (Group 1: from 4.1 ± 2.2 [mean ± SD] at baseline to 6.3 ± 3.5 at 3-month

follow-up; 95% CI: 0.9–4; Group 2: from  $3.6 \pm 1.9$  at baseline to  $8.6 \pm 4.2$  at 3-month follow-up; 95% CI: 2.8–7.1;  $P = 0.016$ ); serum AMH levels were significantly reduced at 3 months in Group 1 (from  $2.6 \pm 1.4$  ng/mL at baseline to  $1.8 \pm 0.8$  ng/mL at 3-month follow-up; 95% CI:  $-1.3$  to  $-0.2$ ;  $P = 0.012$ ) compared with no reduction in Group 2 (from  $2.3 \pm 1.1$  ng/mL at baseline to  $1.9 \pm 0.9$  ng/mL at 3-month follow-up; 95% CI:  $-1$  to  $-0.2$ ;  $P = 0.09$ ).

**LIMITATIONS, REASON FOR CAUTION:** The key limitations of the trial were the low accuracy of AFC in estimating the ovarian reserve in ovaries with endometriomas, the limited study size and the relatively short follow-up, which do not allow us to draw definitive conclusions.

**WIDER IMPLICATIONS OF THE FINDINGS:** The present study suggests that CO<sub>2</sub> technology may treat endometrioma with minimal damage to the adjacent healthy ovarian tissue; however, this study should be considered as a preliminary clinical trial, intended to stimulate future larger trials to address this clinically relevant issue.

**STUDY FUNDING/COMPETING INTEREST(S):** None.

**TRIAL REGISTRATION NUMBER:** ClinicalTrials.gov NCT03227640.

**TRIAL REGISTRATION DATE:** 9 July 2017.

**DATE OF FIRST PATIENT'S ENROLLMENT:** 24 July 2017.

**Key words:** endometrioma / surgery / CO<sub>2</sub> fiber laser / cystectomy / ovarian reserve / anti-Müllerian hormone / antral follicle count

## Introduction

The most appropriate treatment of endometrioma has been questioned for a long time and is still controversial. Excision of the cyst capsule with the stripping technique (cystectomy) seems to be more beneficial than drainage and ablative techniques since it provides a higher spontaneous pregnancy rate and lower recurrence rate (Dunselman et al., 2014). Recently, however, some concerns have been raised as to the possibility that surgical excision of the endometrioma may negatively impact on the ovarian reserve of the operated ovary; this effect is thought to be related to excessive removal and thermal destruction of healthy ovarian tissue with subsequent loss of ovarian follicles (Busacca et al., 2006; Benaglia et al., 2010). According to a recent report, absence of follicular growth was observed in 13% of operated ovaries, although this event never occurred in the contralateral gonad (Benaglia et al., 2010). Moreover, poorer responses to gonadotrophin stimulation for IVF have been reported for ovaries following excisional surgery (Somigliana et al., 2003).

In our Institutions, concerns about ovarian failure after cystectomy resulted in the introduction of an ablative technique involving CO<sub>2</sub> laser technology, which has the ability to deliver energy with little thermal spread, unlike other energy sources such as diathermy. It provides a precise tissue dissection, ablation, controlled depth of tissue penetration and thermal damage; for these reasons, endometrioma ablation using laser energy may represent a less destructive approach towards the healthy ovarian cortex compared to other energy sources (e.g. electrocoagulation). This surgical procedure was inspired by the one employed by Jacques Donnez for more than 20 years in which a CO<sub>2</sub> laser was used to ablate the endometrioma inner wall, after 3 months of GnRH agonist (GnRHa) therapy (Donnez et al., 1996). Laser vaporization, according to the 'three-step procedure', has also been proposed as the best method to preserve ovarian function (Tsolakidis et al., 2010); moreover, reassuring data on the rate of long-term recurrence after laser vaporization have also recently been published (Carmona et al., 2011).

However, no randomized controlled trials have been conducted to compare cystectomy and 'one-step' CO<sub>2</sub> laser vaporization (without

GnRHa therapy) with respect to the ovarian reserve. We previously showed the benefits of CO<sub>2</sub> laser vaporization on ovarian reserve through a prospective clinical trial assessing the postoperative changes in ovarian reserve in terms of antral follicle count (AFC) and anti-Müllerian hormone levels (AMH). The results of this pilot study supported the positive effects of CO<sub>2</sub> laser on ovarian reserve as demonstrated by higher AFC and no change in AMH levels at 3-month follow-up (Ottolina et al., 2017). In order to provide additional data about the impact of CO<sub>2</sub> laser ablation versus cystectomy on ovarian reserve, a small randomized trial was conducted. The aim of this study was to determine whether and to what extent the two surgical procedures for endometriomas treatment (cystectomy versus CO<sub>2</sub> laser vaporization) may affect ovarian reserve by comparing changes in sonographic AFC and serum AMH concentrations after treatment.

## Materials and Methods

This multicentre randomized study included patients who underwent surgery for primary unilateral or bilateral symptomatic endometriomas at two study centers: San Raffaele Scientific Institute in Milan, Italy and Jagiellonian University Medical College, Cracow, Poland.

Owing to a lack of relevant literature, we initially calculated an estimated population of 100 patients based on the study by Pados et al. (2010), investigating the impact of cystectomy and vaporization with CO<sub>2</sub> laser in-line-of-sight according to the 'three-step procedure' on sonographic indicators of ovarian reserve. In the meantime, a case series with the aim to assess the postoperative changes of ovarian reserve using the 'one-step' fiber laser procedure (Ottolina et al., 2017) was conducted in our Center and results became available just before starting to recruit patients for the randomized study. We therefore decided to base the power calculation of the randomized trial on the findings from our own pilot study. In this case series, a postoperative AFC of  $8.1 \pm 5.1$  after surgical treatment with CO<sub>2</sub> fiber laser was reported. Based on these data, the number of subjects to be enrolled was calculated arbitrarily, assuming a difference of 4.05 in the number of postoperative AFC between the two groups as clinically relevant (this corresponds to a 50% difference when compared to the postoperative AFC observed in the laser group of the pilot study). We set a probability of type I error equal to 0.05, a power of 80% and assumed the

same basal AFC count and standard deviation in the two study groups. We calculated that a sample size of 26 patients per group was needed. Taking into account protocol deviations and withdrawal of consent, we established 30 patients per group to undergo randomization.

The inclusion criteria were: symptomatic (pain and/or infertility) patients of reproductive age; primary unilateral or bilateral endometriomas; largest diameter of the endometrioma  $\geq 3$  and  $\leq 8$  cm. The diameter cutoff was chosen according to previous data present in the literature and guidelines for the management of endometriomas (Dunselman *et al.*, 2014).

The exclusion criteria were: patients aged  $\geq 40$  years; detection of deep infiltrating endometriosis at pre-operative work-up; evidence of adenomyosis at the pre-operative ultrasound; previous surgical procedures on the ovaries; unilateral oophorectomy; previous salpingectomy or hysterectomy; other endocrine diseases such as thyroid disease; hormonal treatment within 3 months of ovarian reserve assessment.

Patients fitting the above inclusion criteria and consenting to participate were randomly assigned according to a computer-generated randomization list generated using the method of simple randomization to allocate them in proportion, at 1:1, either to Group 1 (laparoscopic stripping: cystectomy) or Group 2 (laser vaporization). Randomization assignments were placed into sealed, numbered, opaque envelopes that were opened sequentially once a patient had given her consent to participate. Randomization was assigned by a study co-ordinator (at San Raffaele Scientific Institute) who had no other role in the study.

Operative laparoscopy was performed by a team of surgeons with extensive experience in the treatment of endometriosis (M.C., S.F., E.P., R.J.), during the proliferative phase of the menstrual cycle.

Patients in Group 1 underwent a standardized laparoscopic stripping technique to treat endometriomas.

Patients in Group 2 underwent drainage of the cyst content, irrigation and inspection of its inner wall. A biopsy of the cyst wall was sent for routine histologic examination to confirm the diagnosis of endometriosis. When possible, the cyst was everted in order to expose the inner cystic wall completely. After that, the cystic lining was completely vaporized with CO<sub>2</sub> fiber laser (UltraPulse Duo system, Lumenis Ltd, Yokneam, Israel) in a radial way starting from the center to the periphery, at a power density of 13 W/cm<sup>2</sup>. No suture was placed after vaporization.

In all patients, the diagnosis of endometrioma was confirmed by surgical exploration and histopathologic examination. Endometriosis was staged according to the revised American Society for Reproductive Medicine classification (American Society for Reproductive Medicine, 1997).

Within the month before surgery, patients underwent a gynecologic examination with pelvic ultrasound during the proliferative phase to determine the AFC, and blood samples were taken to determine AMH levels (AMH Gen II ELISA, Beckman Coulter Life Sciences, Indiana, USA) at baseline. Afterwards, at 1 and 3 months after surgery, both AFC and AMH levels were re-evaluated. Patients were then referred to the Endometriosis Outpatient Clinic for further follow-up.

The AFC was assessed by counting the number of follicles with an average diameter of 2–10 mm in both ovaries; the AFC of the operated ovary and the AFC of both ovaries were recorded. During ultrasound examination, the volume of each ovary (at baseline, and 1 and 3 months after surgery) and endometrioma, expressed in cm<sup>3</sup>, was also assessed using the Prolate ellipsoid formula: volume = 0.5233 × D1 (longitudinal) × D2 (transverse) × D3 (anterior–posterior). In addition, the largest diameter of the endometrioma was recorded. Pelvic ultrasound was performed by an experienced ultrasonographer who remained blinded to the type of surgical procedure, at each center (J.O., A.N.). A test of the intraobserver reproducibility for AFC assessment was performed (intraclass correlation coefficient = 0.91, 95% CI: 0.85–0.96).

Total operative time, operative time required to treat endometriomas, estimated blood loss, intraoperative/postoperative complications, length of hospitalization and postoperative evolution of symptoms were recorded.

The primary endpoint was the comparison of the AFC changes after treatment between the two groups. The secondary endpoint was the evaluation of serum AMH modifications before and after treatment between the two groups. We set the change in AFC as the primary outcome of the study since it has the advantage, unlike AMH, of showing the ovarian reserve of a single ovary: the validity of AMH is still debated because the relative contribution of the affected and intact ovaries cannot be definitely discriminated.

The study protocol was reviewed and approved by the Review Boards of participating Institutions before enrollment of the first patient (protocol No.: LASER-LUM). The study was conducted in compliance with the Declaration of Helsinki, as outlined in the International Conference on Harmonization Guidelines for Good Clinical Practice, and applicable regulatory requirements (Trial Registration: [ClinicalTrials.gov](https://clinicaltrials.gov) NCT03227640). All the participating patients provided written informed consent before enrollment into the study.

## Statistical analysis

The normal distribution of continuous variables was evaluated with the Kolmogorov–Smirnov test. Categorical variables were compared by Chi square test and Fisher's exact test. Continuous variables between the study groups were compared using Student's *t*-test, while non-parametric variables were compared using Mann–Whitney test according to data distribution. Linear regression analysis was conducted in order to compare differences between AFC of the operated ovary, AMH levels and ovarian volume at baseline and at 3-month follow-up between the two groups ( $\Delta$ AFC Group 1 versus  $\Delta$ AFC Group 2;  $\Delta$ AMH Group 1 versus  $\Delta$ AMH Group 2;  $\Delta$  ovarian volume Group 1 and  $\Delta$  ovarian volume Group 2), adjusting for patients' age.

Statistical calculations were performed using the Statistical Package for the Social Sciences version 21.0 (SPSS, Chicago, IL, USA). A *P* < 0.05 was considered statistically significant.

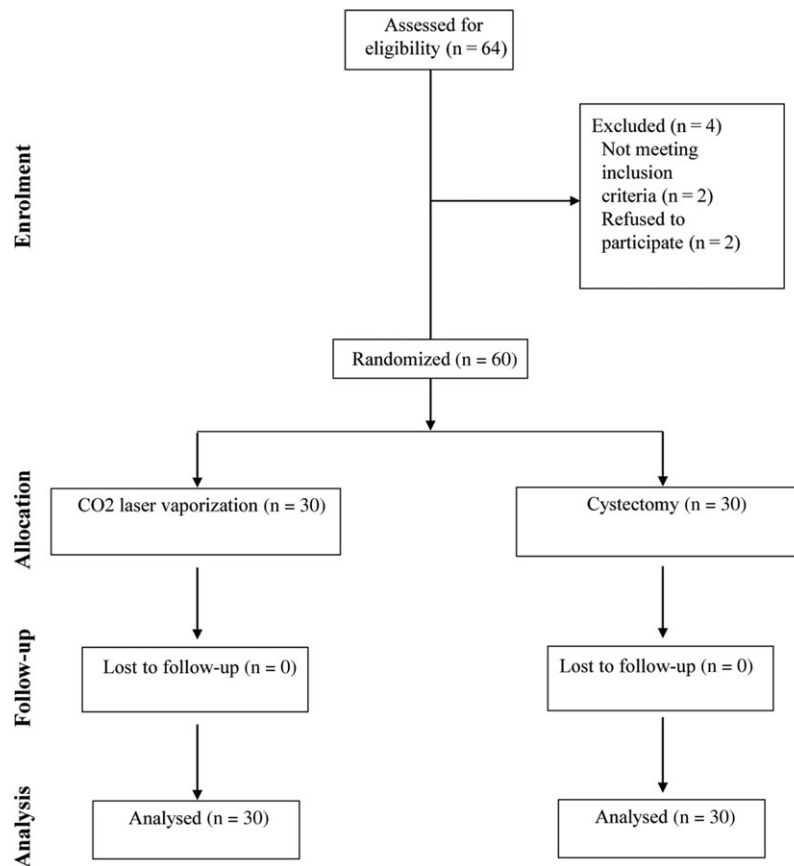
## Results

Between July 2017 and November 2017, 60 women fulfilled the inclusion criteria for the study, agreed to participate, and completed the study (Fig. 1).

The baseline clinical characteristics and ultrasonographic findings of the two study groups are reported in Table I. In particular, there were bilateral endometriomas in three cases in Group 1 and in six cases in Group 2, and these were operated with the same technique (cystectomy or CO<sub>2</sub> laser vaporization) as the contralateral ovary. Also in bilateral endometriomas, baseline characteristics were similar between the two groups.

The operative time, length of hospitalization, follow-up time and postoperative evolution of symptoms are listed in Table II.

$\Delta$ AFC of the operated ovary (at baseline and after 3 months) was found to be significantly higher (adjusted *P* = 0.016, *B* coeff. = 3.41) in Group 2 (from 3.6 ± 1.9 at baseline to 8.6 ± 4.2 at 3-month follow-up; 95% CI: 2.8–7.1) compared with Group 1 (from 4.1 ± 2.2 at baseline to 6.3 ± 3.5 at 3-month follow-up; 95% CI: 0.9–4). No differences emerged from the analysis of  $\Delta$ AFC of the non-operated ovary (baseline and after 3 months) between the two groups (adjusted *P* = 0.43) (data not shown).



**Figure 1** Flow chart of participants from recruitment to follow-up in a study of ovarian reserve after cystectomy versus CO<sub>2</sub> laser vaporization in the treatment of ovarian endometrioma.

A significant difference (adjusted  $P = 0.006$ ,  $B$  coeff. =  $-0.11$ ) regarding  $\Delta$  serum AMH concentrations (at baseline and after 3 months) was observed between the two groups (Group 1: from  $2.6 \pm 1.4$  ng/mL at baseline to  $1.8 \pm 0.8$  ng/mL at 3-month follow-up; 95% CI:  $-1.3$  to  $-0.2$ ; Group 2: from  $2.3 \pm 1.1$  ng/mL at baseline to  $1.9 \pm 0.9$  ng/mL at 3-month follow-up; 95% CI:  $-1$  to  $-0.2$ ).

In the case of bilateral endometriomas, no significant differences emerged in  $\Delta$ AFC (baseline and after 3 months) between Group 1 (from 3.5 at baseline to 11 at 3-month follow-up) and Group 2 (from 9.8 at baseline to 15.1 at 3-month follow-up) nor in  $\Delta$ AMH levels (baseline and after 3 months) between the two groups (adjusted  $P = 0.43$ ).

Comparison of ultrasonographic findings for AFC and serum hormonal concentrations between the two groups before and 3 months after treatment are presented in Table III.

After cyst wall removal in Group 2, ovarian volume was similar in the operated ovary and in the contralateral non-operated ovary ( $7.9 \pm 2.8$  cm<sup>3</sup> and  $8.7 \pm 3.4$  cm<sup>3</sup>;  $P = 0.3$ ); in Group 1, ovarian volume of the operated ovary was smaller when compared with that of the contralateral non-operated ovary ( $5.5 \pm 2.4$  and  $7.8 \pm 3.5$  cm<sup>3</sup>;  $P = 0.019$ ). A linear regression analysis showed a significant difference regarding  $\Delta$  ovarian volume (operated ovary and contralateral non-operated ovary) between the two groups (adjusted  $P = 0.020$ ,  $B$  coeff. =  $2.1$ ).

**Table 1** Baseline clinical characteristics and ultrasonographic findings of the two groups of patients with ovarian endometrioma.

Characteristics	Cystectomy Group 1 (n = 30)	CO <sub>2</sub> laser vaporization Group 2 (n = 30)
Age (years)	30.3 ± 5.2	32.1 ± 4.8
Indications for surgery		
Dysmenorrhea	12 (40)	13 (43.3)
Chronic pelvic pain	18 (60)	16 (53.3)
Dyspareunia	5 (16.7)	4 (13.3)
Infertility	10 (33.3)	11 (36.7)
Pregnancy desire	19 (63.3)	17 (56.7)
BMI (kg/m <sup>2</sup> )	21.8 ± 2.3	20.7 ± 2.9
Diameter of the cyst	4.9 ± 1.5	4.7 ± 1.4
Bilateral endometrioma	3 (10)	6 (20)
Endometriomas in right ovary	15 (50)	15 (50)
Endometriomas in left ovary	18 (60)	21 (70)

Values are mean ± SD or n (%).

**Table II** Surgical characteristics and follow-up of the two groups of patients.

Characteristics	Cystectomy Group 1 (n = 30)	CO <sub>2</sub> laser vaporization Group 2 (n = 30)	P value
Operative time (min)	56.5 ± 22.3	54.3 ± 21	0.66
Operative time for endometrioma (min)	26.8 ± 8.2	23.2 ± 7.9	0.09
Hospital stay (days)	2.3 ± 0.6	2.4 ± 0.6	0.75
Follow-up (months)	7.8 ± 1.5	8.1 ± 1.4	0.8
Postoperative improvement of dysmenorrhea	11/12 (91.7)	12/13 (92.3)	0.6
Postoperative improvement of chronic pelvic pain	15/18 (83.3)	13/16 (81.3)	0.9
Postoperative improvement of dyspareunia	2/5 (40)	2/4 (50)	0.65

Values are mean ± SD or n (%). Data were analyzed using Chi square test, Fisher's exact test, Student's t-test and Mann-Whitney test according to variables type and data distribution.

**Table III** Comparison of the sonographic and serum indicators of ovarian reserve in patients before and 3 months after surgery.

Variable	Cystectomy (n = 30) Group 1 Baseline	Group 1 Month 3	95% CI	P value*	CO <sub>2</sub> laser vaporization (n = 30) Group 2 Baseline	Group 2 Month 3	95% CI	P value*	Adj. P value**
AFC	4.1 ± 2.2	6.3 ± 3.5	0.9–4	0.06	3.6 ± 1.9	8.6 ± 4.2	2.8–7.1	<0.001	<b>0.016</b>
Serum AMH (ng/mL)	2.6 ± 1.4	1.8 ± 0.8	–1.3 – –0.2	0.012	2.3 ± 1.1	1.9 ± 0.9	–1 – –0.2	0.09	<b>0.006</b>

\*Intra-group Student's t-test.

\*\*Linear regression analysis adjusted for patients' age.

Values are mean ± SD.

AFC = antral follicle count (operated ovary).

AMH = anti-Müllerian hormone.

No intraoperative or postoperative complications were reported. No recurrences of endometrioma were reported at a mean follow-up of 7.2 months (range: 6–10).

In this series, 25 patients (41.7%) wished to become pregnant and, following the surgeon's advice, were allowed to attempt a spontaneous conception after surgery (Group 1: n = 13 (43.3%); Group 2: n = 12 (40%), P = 0.09). At a mean follow-up of 5.3 months, two patients (15.4%) in Group 1 and three patients (25%) in Group 2 were pregnant. Eleven patients (Group 1: n = 3; Group 2: n = 8) who were operated because they were symptomatic, were referred to IVF (ongoing) at the end of the 3-month follow-up, considering their age >37 years and the baseline levels of AMH.

The remaining patients who had no immediate pregnancy intention, received medical therapy (estrogen-progestins) at the end of the study.

## Discussion

The present study is the first, although small, randomized trial that compares cystectomy to 'one-step' CO<sub>2</sub> fiber laser vaporization for the management of endometriomas and assesses the impact of both techniques on ovarian reserve. Our results suggest that ablation with CO<sub>2</sub> laser technology is associated with a more significant increase in the AFC of the operated ovary compared to the values observed after cystectomy. Our study is supported by previous ones suggesting that

endometrioma ablation using energies with minor in depth thermal spread, such as CO<sub>2</sub> laser and plasma energy, may represent an effective ovarian tissue-sparing technique (Canis *et al.*, 2001; Tsolakidis *et al.*, 2010; Var *et al.*, 2011; Roman *et al.*, 2013). Increasing evidence exists about the risk of reducing ovarian reserve following cystectomy because of the inadvertent removal of healthy ovarian cortex together with the endometrioma wall, and the amount of ovarian tissue removed inversely correlates to the level of surgical expertise and directly correlates to the cyst size (Muzii *et al.*, 2007, 2011; Roman *et al.*, 2010).

Nevertheless, a large majority of surgeons abandoned ablative techniques after a 2008 Cochrane review (Hart *et al.*, 2008) reporting better outcomes with stripping techniques with respect to cyst ablation in terms of recurrence of endometrioma and spontaneous pregnancy rates. However, based on only three older randomized trials, the validity of this Cochrane review has been questioned, especially as the ablation group consisted of bipolar energy only, which is most likely responsible for a deeper thermal effect, not taking into account results from CO<sub>2</sub> laser or plasma energy studies, which have a low thermal spread (Daniell *et al.*, 1991; Donnez *et al.*, 1996, 2004; Sutton and Jones, 2002; Roman *et al.*, 2011).

There are consistent data in the literature about the safety and efficacy of CO<sub>2</sub> laser technology: according to Donnez *et al.* (2001), ablation cannot penetrate into the tissue by more than 1.0–1.5 mm.

Therefore, this technique appears to destroy the filmy superficial internal lining of the cyst selectively (the glandular epithelium and sub-adjacent stroma), without reaching the fibrotic capsule surrounding the endometrioma or the adjacent healthy ovarian cortex.

Based on this evidence, since 2015 we have adopted the CO<sub>2</sub> fiber laser for use in the surgical treatment of ovarian endometriosis (without GnRHa therapy before surgery). CO<sub>2</sub> fiber laser vaporization may represent a more advantageous approach than other energy sources (CO<sub>2</sub> laser in-line-of-sight or plasma laser) for several reasons. It is simple, easy to use and highly reproducible (Vanni et al., 2018), and thanks to its high precision provides optimal coagulation and ablation capabilities, minimizing the need for electrocoagulation or suturing. Thanks to its low thermal energy, it avoids excessive ischemia and allows safe management of delicate tissues, such as ovarian parenchyma. Moreover, the long arm of the flexible fiber allows the surgeon to reach narrow anatomical spaces, and it can be introduced in the peritoneal cavity from any laparoscopic access, allowing the surgeon the optimal approach to the operative field.

We have previously reported the positive effects of CO<sub>2</sub> laser on ovarian reserve in a prospective clinical trial assessing the post-operative changes in ovarian reserve of 15 patients who had their endometrioma vaporized with CO<sub>2</sub> fiber laser (Ottolina et al., 2017). The results showed a higher AFC and no change in AMH levels at 3-month follow-up compared to baseline.

In order to provide additional data about the potential advantage of using CO<sub>2</sub> laser ablation over ovarian cystectomy on ovarian reserve, a randomized trial was conducted. Our results, showing a significant improvement in the AFC of the operated ovary after CO<sub>2</sub> laser vaporization compared to cystectomy, reinforce those of Pados et al. (2010) who found an increase in AFC in the treated ovary 6 months after the 'three-stage procedure' and of Donnez et al. (2010) who reported AFC values similar to those of the contralateral ovary after using a combined excisional and ablative technique; however, these studies have several limitations, i.e. the small sample size and the non-randomized design of the trial.

We reported a significant decrease in serum AMH levels in the cystectomy group, whereas no change in AMH levels was found after laser vaporization; these positive findings are consistent with those reported by Tsolakidis et al. (2010) and could be related to CO<sub>2</sub> laser technology; however, differences between  $\Delta$ AMH may be considered too small to be clinically relevant. Moreover, in patients randomized to laser vaporization, we have demonstrated similar ovarian volumes between the operated ovary and the contralateral non-operated ovary. These results support other published data (Donnez et al., 2010), and suggest a possible role of CO<sub>2</sub> laser in preserving a normal ovarian volume.

No recurrences of endometriomas were reported in either group, even though no definitive conclusion can be drawn due to the short-term follow-up. However, reassuring data on the rate of long-term recurrence after laser vaporization have also recently been published: Carmona and his colleagues reported a statistically significant increase in short-term recurrence rates in patients undergoing laser treatment compared to cystectomy; however, no statistically significant differences in long-term (5 years) recurrence rates were found between cystectomy and CO<sub>2</sub> laser vaporization (Carmona et al., 2011).

However, this study has several weaknesses. The major limitation is represented by the use of AFC in estimating the ovarian reserve in

ovaries with endometriomas. The presence of a large endometrioma may impair the sonographic identification of small follicles adjacent to the cyst and, consequently, ovarian reserve could be underestimated before surgery. This could be the reason why the AFC of the operated ovary has been shown to increase in both groups after treatment. However, besides AFC changes after surgery, AMH levels have also been analyzed. No significant differences emerged in AMH levels before and after laser vaporization, whereas serum AMH levels were significantly reduced after cystectomy. Therefore, CO<sub>2</sub> laser may have less harmful effects on the ovarian tissue compared to cystectomy.

Moreover, the sample size is small, thus estimation of results may be less precise. This is a small randomized trial with sufficient statistical power to detect only large differences in primary endpoint between the two groups. It should be pointed out that a larger population would allow a more precise estimation of difference in primary endpoint between the two groups of treatment. Therefore, the present study should be considered as a preliminary clinical trial where the number of patients recruited was probably small from a biometric point of view, but it is intended to stimulate future larger trials to address this clinically relevant issue.

Another limitation of the study is the relatively short follow-up and the subsequent inability to measure a conclusive pregnancy rate. However, some authors suggested that the traumatic damage inflicted to the ovarian cortex following endometrioma surgery is immediate and a recovery is possible in the early postoperative period (as early as 3 months after surgery), when edema and local inflammation end (Chang et al., 2010; Roman et al., 2014). For this reason, we considered 3-month follow-up as an optimal time to evaluate the ovarian reserve. Moreover, pregnancy rate was not within the outcomes we set for this study.

In conclusion, this study suggests that CO<sub>2</sub> fiber laser may treat endometrioma with minimal damage to the adjacent healthy ovarian tissue. Additional well-designed trials are needed to verify changes in AFC and AMH at a longer follow-up and to address the fertility outcomes.

## Authors' roles

M.C.: Conception and design of the study, data analysis and interpretation, article preparation and revision, final approval. J.O.: Data acquisition, data analysis and interpretation, statistical analysis, article preparation and revision, final approval. E.P.: Data acquisition, patient recruitment, article preparation, final approval. S.F.: Patient recruitment, data analysis and interpretation, article preparation, final approval. L.M.C.: Data acquisition, patient recruitment, article preparation, final approval. I.T.: Patient recruitment, data analysis and interpretation, article preparation, final approval. L.P.: data analysis and interpretation, statistical analysis, article preparation, final approval. A.N.: Data acquisition, patient recruitment, article preparation, final approval. R.J.: conception and design of the study, data analysis and interpretation, article preparation and revision, final approval.

## Funding

None.

## Conflict of interest

None.

## References

- American Society for Reproductive Medicine. Revised American Fertility Society classification of endometriosis: 1996. *Fertil Steril* 1997;**67**:817–821.
- Benaglia L, Somigliana E, Vighi V, Ragni G, Vercellini P, Fedele L. Rate of severe ovarian damage following surgery for endometriomas. *Hum Reprod* 2010;**25**:678–682.
- Busacca M, Riparini J, Somigliana E, Oggioni G, Izzo S, Vignali M, Candiani M. Postsurgical ovarian failure after laparoscopic excision of bilateral endometriomas. *Am J Obstet Gynecol* 2006;**195**:421–425.
- Canis M, Pouly JL, Tamburro S, Mage G, Wattiez A, Bruhat MA. Ovarian response during IVF-embryo transfer cycles after laparoscopic ovarian cystectomy for endometriotic cysts of >3 cm in diameter. *Hum Reprod* 2001;**16**:2583–2586.
- Carmona F, Martínez-Zamora MA, Rabanal A, Martínez-Román S, Balasch J. Ovarian cystectomy versus laser vaporization in the treatment of ovarian endometriomas: a randomized clinical trial with a five-year follow-up. *Fertil Steril* 2011;**96**:251–254.
- Chang HJ, Han SH, Lee JR, Jee BC, Lee BI, Suh CS, Kim SH. Impact of laparoscopic cystectomy on ovarian reserve: serial changes of serum antimüllerian hormone levels. *Fertil Steril* 2010;**94**:343–349.
- Daniell JF, Kurtz BR, Gurley LD. Laser laparoscopic management of large endometriomas. *Fertil Steril* 1991;**55**:692–695.
- Donnez J, Lousse JC, Jadoul P, Donnez O, Squifflet J. Laparoscopic management of endometriomas using a combined technique of excisional (cystectomy) and ablative surgery. *Fertil Steril* 2010;**94**:28–32.
- Donnez J, Nisolle M, Gillet N, Smets M, Bassil S, Casanas-Roux F. Large ovarian endometriomas. *Hum Reprod* 1996;**11**:641–646.
- Donnez J, Pirard C, Smets M, Jadoul P, Squifflet J. Surgical management of endometriosis. *Best Pract Res Clin Obstet Gynaecol* 2004;**18**:329–348.
- Donnez J, Wyns C, Nisolle M. Does ovarian surgery for endometriomas impair the ovarian response to gonadotropin? *Fertil Steril* 2001;**76**:662–665.
- Dunselman GA, Vermeulen N, Becker C, Calhaz-Jorge C, D'Hooghe T, De Bie B, Heikinheimo O, Horne AW, Kiesel L, Nap A et al. ESHRE guideline: management of women with endometriosis. *Hum Reprod* 2014;**29**:400–412.
- Hart R, Hickey M, Maouris P, Buckett W. Excisional surgery versus ablative surgery for ovarian endometrioma. *Cochrane Database Syst Rev* 2008;**16**:CD004992.
- Muzii L, Bianchi A, Bellati F, Cristi E, Pernice M, Zullo MA, Angioli R, Panici PB. Histologic analysis of endometriomas: what the surgeon needs to know. *Fertil Steril* 2007;**87**:362–366.
- Muzii L, Marana R, Angioli R, Bianchi A, Cucinella G, Vignali M, Benedetti Panici P, Busacca M. Histologic analysis of specimens from laparoscopic endometrioma excision performed by different surgeons: does the surgeon matter? *Fertil Steril* 2011;**95**:2116–2119.
- Ottolina J, Castellano LM, Ferrari S, Tandoi I, Candotti G, De Stefano F, Bartiromo L, Candiani M. The impact on ovarian reserve of CO<sub>2</sub> laser fiber vaporization in the treatment of ovarian endometrioma: a prospective clinical trial. *J Endometr Pelvic Pain Disord* 2017;**9**:206–210.
- Pados G, Tsolakidis D, Assimakopoulos E, Athanatos D, Tarlatzis B. Sonographic changes after laparoscopic cystectomy compared with three-stage management in patients with ovarian endometriomas: a prospective randomized study. *Hum Reprod* 2010;**25**:672–677.
- Roman H, Auber M, Bourdel N, Martin C, Marpeau L, Puscasiu L. Postoperative recurrence and fertility after endometrioma ablation using plasma energy: retrospective assessment of 3-year experience. *J Minim Invasive Gynecol* 2013;**20**:573–582.
- Roman H, Auber M, Makdad C, Martin C, Diguët A, Marpeau L, Bourdel L. Ovarian endometrioma ablation using plasma energy versus cystectomy: a step toward better preservation of the ovarian parenchyma in women wishing to conceive. *Fertil Steril* 2011;**96**:1396–1400.
- Roman H, Bubenheim M, Auber M, Marpeau L, Puscasiu L. Antimüllerian hormone level and endometrioma ablation using plasma energy. *JSL* 2014;**18**:1–11.
- Roman H, Tarta O, Pura I, Opris I, Bourdel N, Marpeau L, Sabourin JC. Direct proportional relationship between endometrioma size and ovarian parenchyma inadvertently removed during cystectomy, and its implication on the management of enlarged endometriomas. *Hum Reprod* 2010;**25**:1428–1432.
- Somigliana E, Ragni G, Benedetti F, Borroni R, Vegetti W, Crosignani PG. Does laparoscopic excision of endometriotic ovarian cysts significantly affect ovarian reserve? Insights from IVF cycles. *Hum Reprod* 2003;**18**:2450–2453.
- Sutton CJG, Jones KD. Laser laparoscopy for endometriosis and endometriotic cysts. *Surg Endosc* 2002;**16**:1513–1517.
- Tsolakidis D, Pados G, Vavilis D, Athanatos D, Tsalikis T, Giannakou A, Tarlatzis BC. The impact on ovarian reserve after laparoscopic ovarian cystectomy versus three-stage management in patients with endometriomas: a prospective randomized study. *Fertil Steril* 2010;**94**:71–77.
- Vanni VS, Ottolina J, Candotti G, Castellano LM, Tandoi I, De Stefano F, Poppi G, Ferrari S, Candiani M. Does flexible CO<sub>2</sub> laser fiber have a potential in surgery for endometriosis? A first look at the learning curve required. *Minerva Ginecol* 2018;**70**:53–57.
- Var T, Batioglu S, Tonguc E, Kahyaoglu I. The effect of laparoscopic ovarian cystectomy versus coagulation in bilateral endometriomas on ovarian reserve as determined by antral follicle count and ovarian volume: a prospective randomized study. *Fertil Steril* 2011;**95**:2247–2250.